

*Original research***Management of Skeletal Class III Malocclusion in an Early Mixed Dentition with Face Mask Therapy: A Case Report**

Singh K, Verma VK, Panda S, Sachan A

Abstract: A developing skeletal Class III malocclusion is one of the most challenging problems for the orthodontists. Whether to start early treatment or wait for growth to be over is still an ongoing debate. Interception of mild to moderate cases should be carried out as early as possible before it becomes severe. This is a case report of successful treatment of developing skeletal class III malocclusion in a 6 year-old female patient in early mixed dentition with a mesial step molar relation, an anterior negative overjet, and skeletal Class III due to a deficient maxilla. The treatment objective was to correct the skeletal class III to achieve a more harmonious facial profile. The treatment plan included protraction of the maxilla by a reverse pull Delaire type facemask. The post treatment results showed a significant improvement in Class III skeletal relationship, negative overjet and facial profile with class I molar relationship.

Keywords: Class III; Maxillary Deficiency; Delaire Facemak; Early Mixed Dentition; Facial; Molar.

INTRODUCTION

The etiology of Class III malocclusion is believed to be mainly hereditary, but environmental factors like habits and mouth breathing may also play a role.^{1,2} The prevalence of Class III malocclusion varies among different ethnic groups. The incidence in Caucasians ranges between 1% and 4%³, but is higher in Asians (4-14%) due to a large percentage of patients with maxillary deficiency.⁴ Individuals with Class III malocclusion may have combinations of both skeletal and dentoalveolar components. The skeletal components include underdeveloped maxilla, overdeveloped mandible or a combination of both; dentoalveolar components include proclined maxillary incisors, and retroclined mandibular incisors, to achieve dentoalveolar compensation⁵. Ellis and McNamara⁶ found that 65-67% of all Class III malocclusions were characterized by maxillary retrognathism.

The objective of early orthodontic treatment is to create an environment in which more favorable dentofacial developments can occur⁷. The goals of early Class III treatment may include prevention of progressive irreversible soft tissue or bony changes such as abnormal wear of the lower incisors, dental compensation of mandibular incisors, leading

to thinning of the labial alveolar plate and/or gingival recession due to uncorrected anterior crossbite. It will improve skeletal discrepancies and provides a more favorable environment for future growth. Early orthopaedic treatment using facemask or chin cup therapy improves the skeletal relationships, minimizing excessive dental compensation such as overclosure of the mandible and retroclination of the mandibular incisors. It will also improve occlusal function by eliminating centric occlusion/centric relation (CO/ CR) discrepancies due to functional shift cause by anterior cross bite and avoid adverse growth potential. It will help simplify phase II comprehensive treatment⁸. In mild and moderate Class III patients, early orthodontic or orthopedic treatment may eliminate the necessity for orthognathic surgery treatment. Even if surgery is eventually needed, early correction of the transverse dimension and maximizing the growth potential of the maxilla may minimize the extent of the surgical procedures. It provides more pleasing facial esthetics (the lip posture and facial appearance), thus improving the psychosocial development of a child.^{9,2}

The advantage of expansion in these patients is to correct the posterior cross bite, and disarticulate the maxilla. Face masks therapy with and without an associated RME

improved skeletal Class III malocclusion by a combination of skeletal and dental changes. These results suggested that the use of an RME should be based on clinical criteria rather than assisting the Class III correction.¹⁰

CASE REPORT

A female patient aged 6 years, came to the Department of Orthodontics with the chief complaint of forward placement of lower front teeth and depressed upper lip. No familial history of similar malocclusion was noted. Extra oral examination revealed (Fig 1) she had symmetrical, leptoprosopic face and with a straight profile and flat midface. She had an obtuse nasolabial angle, and shallow mentolabial sulcus. The smile was unesthetic because of lack of display of maxillary anterior teeth.

Intraoral examination (Fig 2) revealed the presence of mixed dentition of teeth with the presence of all permanent first molars and 11, 21, 31, 32, 41, 42 in upper and lower arches, 12 and 22 were in erupting stage. Mandibular deciduous second molars showed a mesial step relation to the maxillary deciduous second molars, and 11, 12, 21, 22 were in crossbite relation to 31, 32, 41, 42, 73, and 83. Mild crowding in lower arch and bilateral posterior cross bite was present. A reverse overjet of 1 mm and overbite of 3 mm was present.

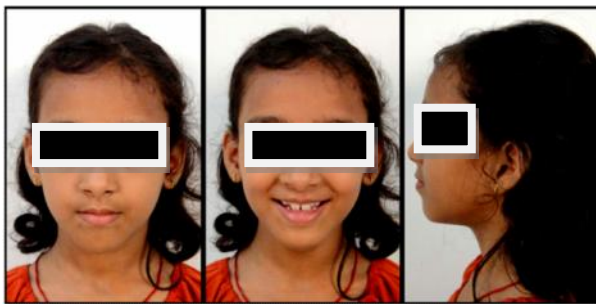

Figure:1. Pretreatment facial photographs

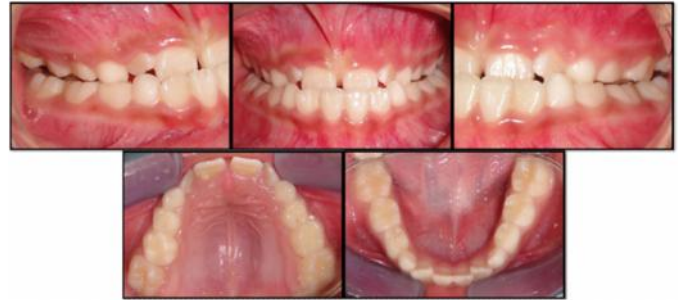

Figure: 2 Pretreatment intraoral photographs

The panoramic findings (Fig 3) revealed the presence of early mixed dentition with erupted permanent first molars, upper and lower central and lateral incisors; canines, and first and second premolars in an erupting stage.

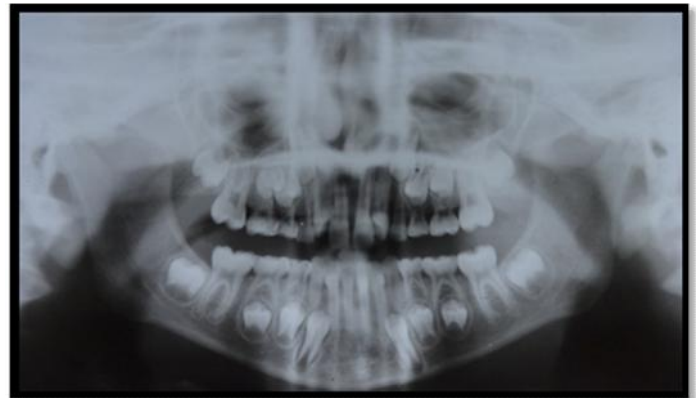

Figure: 3. Pretreatment OPG

The cephalometric findings (Fig 4) revealed the patient in CS1 stage of CVMI, a skeletal class III relationship (SNA 77°, SNB 78°, ANB -1°, Wits -8.5 mm) characterized by maxillary deficiency with slight vertical growth pattern (GoGn-SN 32°, FMA 29°). The upper incisors were retruded (UI-NA 22°/0 mm) and the lower anteriors were retruded (LI-NB 26°/4 mm). The upper lip was retruded (UL- E-line - 2 mm) and lower lip protruded (UL- E-line + 5 mm).

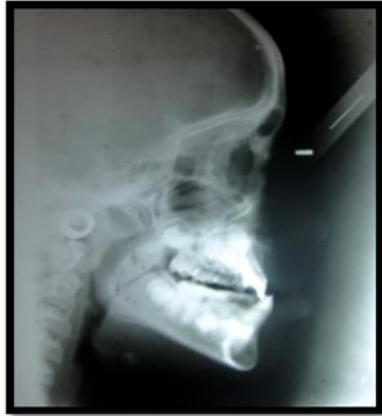

Figure: 4 Pretreatment Lateral Cephalogram

Diagnosis: The patient was diagnosed as developing skeletal class III malocclusion due to maxillary deficiency, slight vertical growth pattern with a mesial step relation of the maxillary deciduous second molars along with reverse overjet, retroclined upper and lower incisors, and mild crowding in relation to lower anterior.

Treatment objectives were to correct Class III skeletal relationship, to establish proper occlusion i.e attaining positive overjet and class III molars and obtain an esthetic smile with pleasing soft tissue profile and facial pattern.

Treatment plan included maxillary protraction with orthopedic appliance therapy i.e. a Delaire type of Face mask along with a cap type of maxillary acrylic splint, followed by retention.

Treatment progress:

The Delaire facemask [Fig 5 (a)] was used in this patient to protract the deficient maxilla and restrict mandibular growth. It consists of two anchorage units, i.e. forehead and chin pads, interconnected by a heavy steel metal framework and an adjustable horizontal steel framework at the occlusal level for force application. Intraoral appliance consisted of a removable cap type of acrylic splint on maxillary arch¹² [Fig 5 (b)]. The protraction elastics were applied between the SS hooks (a

hook of 1 mm stainless steel were fabricated and were positioned between the deciduous canines and the first molars. The open end of the hook was directed distally for engaging extra-oral elastics) of the splint to the facemask, directed downward at an angle of 30° to the occlusal plane. A force of approximately 400 g per side was recommended. The patient was instructed to wear the facemask for a minimum of 12-14 h/day.

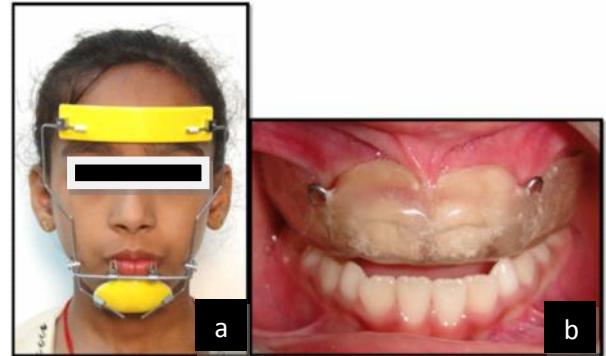


Figure: 5 (a) Delaire facemask (b) Intra oral removable cap type of acrylic splint

After nine months, treatment was completed once the anterior crossbite was corrected satisfactorily and the face mask was only used as a night retention appliance. The post-treatment facial photographs showed a significant improvement in facial profile (Fig 6).

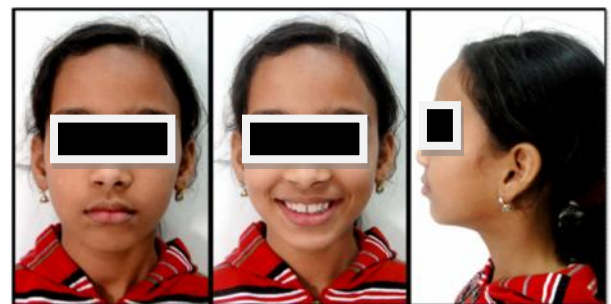

Figure: 6 Post treatment Extraoral Photographs

Flat midface improved because of forward movement of maxilla and the profile became mild convex due to clockwise rotation of the mandible. There was improvement in the smile with increase in display of maxillary incisors on smiling. The intraoral photographs

revealed establishment of the positive overjet and well settled occlusion (Fig 7).

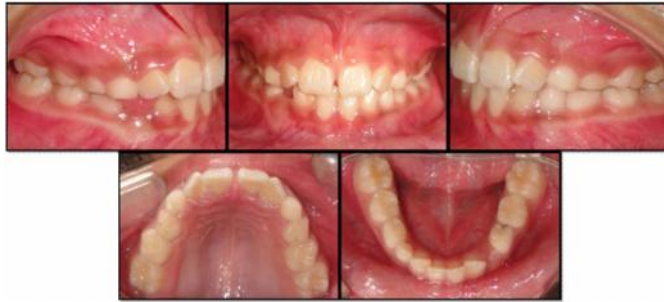

Figure: 7 Post treatment Intraoral Photographs

Post-treatment cephalometric values (Table: 1, Figure: 8) revealed positive sagittal alterations, i.e. as skeletal pattern, approached a class I. The ANB angle increased by 4° (SNA 79° , SNB 75°), Wits -2 mm, along with proclination and forward displacement of upper incisors (UI to NA $24^{\circ}/+3$ mm). There was a significant improvement in upper lip protrusion (UL-E line $+2$ mm).

Table: 1- Cephalometric Measurements

CEPALOMETRIC VARIABLES	PRE TREATMENT VALUES	POST TREATMENT VALUES
SNA	75°	79°
SNB	77°	75°
ANB	-1°	4°
Wits	-8.5 mm	-2 mm
SN-GoGn	32°	33°
FMA	29°	30°
UI-NA ($^{\circ}$)	22°	24°
UI-NA (mm)	0 mm	$+3$ mm
LI-NB ($^{\circ}$)	26°	25.5°
UI-NA (mm)	4 mm	3.5 mm
UPPER LIP – E-LINE (mm)	-2 mm	$+2$ mm
LOWER LIP – E-LINE (mm)	$+5$ mm	$+4$ mm

Thus, the extraoral examination and radiographic findings indicated forward protraction of the maxilla, proclination of maxillary incisors, slight retroclination of

mandibular incisors, positive overjet of teeth and improvement of facial profile.

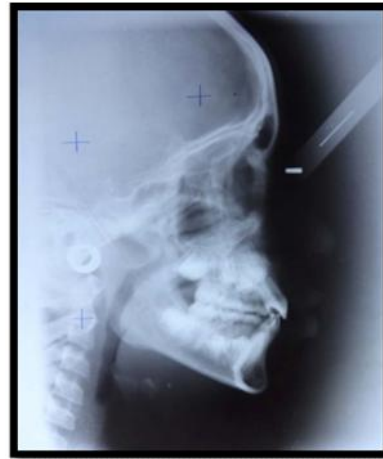

Figure: 8 Post Treatment Lateral Cephalogram

Discussion

Class III malocclusions are often seen with maxillary retrognathia, mandibular prognathia, or a combination of both. Thus, maxillary protraction is an emerging trend in the early management of skeletal Class III malocclusion. In 1960's a "Protraction Headgear" was developed which used chin and top of the head for support. The effects of protraction therapy in postpubertal subjects with Class III malocclusion and concluded that the orthopedic treatment was more effective when it was initiated at an early developmental phase of the dentition (early mixed or late deciduous) rather than during later stages with respect to untreated Class III control groups. Itoh et al¹¹ and Hata et al¹² said that there was a possibility of anterior maxillary constriction when the maxilla was protracted. This was also counteracted by rapid palatal expansion appliances. A recent study by Kim et al¹³ involving a meta analysis on 440 articles relating to Class III malocclusion confirmed that maxillary protraction concluded that the results of protraction were similar in both expansion and non expansion group, the average duration was much higher in the non-expansion group. Thus the same degree of improvement was

obtained within a shorter period of time with the expansion appliance. Recent randomized controlled trial on the effects of maxillary protraction therapy with or without rapid palatal expansion by Vaughn et al¹⁴ reported no significant differences between expansion and nonexpansion groups in any measured variable. An in vitro study, using a 3-D finite element method, found that an anteriorly directed force applied to the buccal surfaces of the maxillary first molar with a downward pull from 30-45° to the occlusal plane gave the most translatory effect.¹⁵ The treatment effects of the protraction facemask therapy were a combination of skeletal and dental changes of the maxilla and mandible.

The maxilla moved downward and forward with a slight upward movement in the anterior and downward movement in the posterior palatal plane as the result of protraction force; at the same time posterior teeth extruded somewhat. As a consequence, downward and backward rotation of the mandible improved the maxillomandibular skeletal relationship in the sagittal dimension but resulted in an increased lower facial height. This rotation was a major contributing factor in establishing an anterior overjet improvement.

Thus, Class III malocclusion should be intercepted as early as possible to permit growth redirection, mainly when the maxilla is the primary etiologic factor or dental and/or functional factors are involved.

CONCLUSION: The present case shows the correction of skeletal Class III malocclusion in a six-year-old female, in CS1 stage of CVMI, with protraction facemask therapy without an associated RME by combination of skeletal and dental changes. There was forward displacement of the maxilla, proclination of maxillary incisors, positive overjet, more convex profile and improvement in the smile. Thus proper diagnosis, treatment planning and prognosis of a developing Class III malocclusion depend on patient age, growth potential and severity of malocclusion. Early intervention, adequate indication of

appliances, and patient compliance are key factors for good outcomes.

Authors affiliation: 1. Karuna Singh , MDS, Senior Lecturer, 2. Vinay Kumar Verma, MDS, Professor & HOD, 3. Sujit Panda, MDS, Professor, 4. Sachan Avesh, MDS, Reader, Department of Orthodontics, Rama Dental College, Kanpur, Uttar Pradesh, India.

REFERENCES

1. Litton SF, Ackermann LV, Isaacson RJ, Shapiro BL. A genetic study of Class 3 malocclusion. *Am J Orthod* 1970; 58:565-77.
2. Rakosi T, Schilli W. Class III anomalies: A coordinated approach to skeletal, dental, and soft tissue problems. *J Oral Surg* 1981; 39:860-70.
3. Newman GV. Prevalence of malocclusion in children six to fourteen years of age and treatment in preventable cases. *J Am Dent Assoc* 1956; 52:566-75.
4. Ishii H, Morita S, Takeuchi Y, Nakamura S. Treatment effect of combined maxillary protraction and chin cap appliance in severe skeletal Class III cases. *Am J Orthod Dentofacial Orthop* 1987; 92:304-12.
5. Ngan P, Hu AM, Fields HW. Treatment of Class III problems begins with differential diagnosis of anterior crossbites. *Pediatr Dent* 1997; 19:386-95.
6. Ellis E, McNamara JA Jr. Components of adult Class III open-bite malocclusion. *Am J Orthod*. 1984 Oct; 86(4):277-90.
7. Joondeph DR: Early orthodontic treatment. *Am J Orthod Dentofacial Orthop* 1993; 104:199-200.
8. Avesh Sachan, TP Chaturvedi, Adit, Ajit Parihar, treatment of Class III malocclusion with impacted canines, *J of Clinical Dentistry*: 2012;6(1):72-77.
9. Ngan P, Hägg U, Yiu C, Merwin D, Wei SH. Soft tissue and dentoskeletal profile changes associated with maxillary expansion and protraction headgear treatment. *Am J Orthod Dentofacial Orthop* 1996; 109:38-49.
10. Yavuz I, Halicio lu K, Ceylan I, Da suyu IM, Erdem A. The effects of face

mask therapy with and without rapid maxillary expansion in adolescent patients. Aust Orthod J. 2012; 28(1):63-71.

11. Itoh T, Chaconas SJ, Caputo AA, Matyas J. Photoelastic effects of maxillary protraction on the craniofacial complex. Am J Orthod. 1985; 88(2):117-24.

12. Hata S, Itoh T, Nakagawa M, Kamogashira K, Ichikawa K, Matsumoto M, Chaconas SJ. Biomechanical effects of maxillary protraction on the craniofacial complex. Am J Orthod Dentofacial Orthop 1987; 91:305-11.

13. Kim JH, Viana MA, Graber TM, Omerza FF, BeGole EA. The effectiveness of protraction face mask therapy: a meta-analysis. Am J Orthod Dentofacial Orthop. 1999; 115(6):675-85.

14. Vaughn, G.A., Mason, B., Moon, H.-B., Turley, P.K. The effects of maxillary protraction therapy with or without rapid palatal expansion: A prospective, randomized clinical trial Am J of Orthod Dentofacial Orthop, 2005;128(3):299-309.

15. Tanne K, Hiraga J, Sakuda M. Effects of directions of maxillary protraction forces on biomechanical changes in craniofacial complex. Eur J Orthod. 1989; 11(4):382-91.

Corresponding author:

Karuna Singh, Senior Lecturer,
Department of Orthodontics,
Rama Dental College,
Kanpur, Uttar Pradesh, India.

E-mail - drkarunachib@yahoo.co.in

How to cite this article:. Singh K, Verma VK, Panda S, Sachan A. Management of Skeletal Class III Malocclusion in an Early Mixed Dentition with Face Mask Therapy: A Case Report. J Dent Res Updates 2014 Dec;1(1):55-60

Sources of support: Nil

Conflict of Interest: None declared