

Case Report

Early Orthodontic Treatment of Unusual Trauma Caused by Ectopically Erupted Maxillary Central Incisor

Verma VK, Ashok P, Sachan A, Badhauria V

Abstract: Ectopic eruption or impaction of permanent maxillary incisors is an unusual outcome of traumatic injury or intrusive luxation to their predecessors. In this case report, we describe management of the consequences of a primary tooth intrusion that led to severe ectopic eruption of the permanent left central incisor in a horizontal position at the level of the labial sulcus. The ectopic incisor was moved into its proper position with surgical exposure and orthodontic traction. After which it showed good long-term periodontal stability.

Keywords: Ectopic eruption, Traumatic injury, surgical exposure, Orthodontic force.

INTRODUCTION

Although ectopic eruption of a permanent tooth is rarely diagnosed during the mixed dentition period, an ectopic central incisor is usually diagnosed accurately when there is delay in the eruption of the tooth or soft tissue irritation of oral mucosa. Many patients with ectopic maxillary central incisors are referred to orthodontists by general practitioners or pediatric dentists because parents are concerned about the unusual position of an incisor in the early mixed dentition. Careful planning is required when moving an ectopic tooth by orthodontic treatment. Ectopic teeth can be properly positioned with orthodontic traction. Ectopic eruption of a permanent incisor may result from traumatic injury to its predecessor.¹

The condition is caused by the physical displacement of the permanent germ, the lack of eruption guidance by the prematurely lost primary incisor or both. Although ectopic eruption of the maxillary central incisor is almost as prevalent as ectopic eruption of the canines, its etiology is different. The principal factors involved are trauma, supernumerary teeth and odontomas.²

According to the literature, 15%–30% of children suffer traumatic injuries to primary teeth.³⁻⁵ Intrusive luxation constitute 4.4%–22% of traumatic injuries in primary dentition. Intruded primary tooth due trauma cause developmental disturbances of the successor permanent tooth can occur as a result of the close proximity of the developing permanent tooth germ to the primary root apex.

These traumatic disturbances include white or yellow brown enamel discoloration with or without enamel hypoplasia, crown–root dilacerations, odontoma, root duplication or angulation, arrest of root development, germ sequestration ectopic eruption and impaction.⁶⁻⁸ In this case report, we describe the management of a permanent central incisor that was erupting ectopically because of prior intrusive injury of the corresponding primary tooth.

CASE REPORT

A healthy 10-year-old north Indian boy was referred to the orthodontic department with the chief complaint of swelling in upper lip and ectopic eruption of the maxillary left central incisor. Reportedly, at 4 or 5 years of age he had experienced a fall that caused severe intrusion of his primary left central incisor and premature loss of the tooth few months later. Intraoral examination revealed the absence of the maxillary left central incisor within the dental arch, along with slight closure of the eruption space caused by displacement of the neighboring incisors

The central incisor could only be visualized when the patient's upper lip was stretched up and outward as much as possible. Incisal edge of ectopically erupting incisor causes severe laceration trauma to upper lip mucosa. Previous Trauma to primary tooth had caused displacement of the permanent tooth to an almost horizontal position at the level of the labial sulcus, forcing the incisor to erupt toward the inner labial mucosa. Over time, chronic soft-tissue irritation caused by the tooth's incisal aspect had caused formation of a "pseudo-pouch" with

a swollen, elevated border that overlapped the crown in the resting position of the lip.

Stretching of the upper lip also revealed a purulent exudation that had accumulated

within the pouch. An OPG and intra oral peri-apical radiograph showed horizontal position of left upper central incisor.

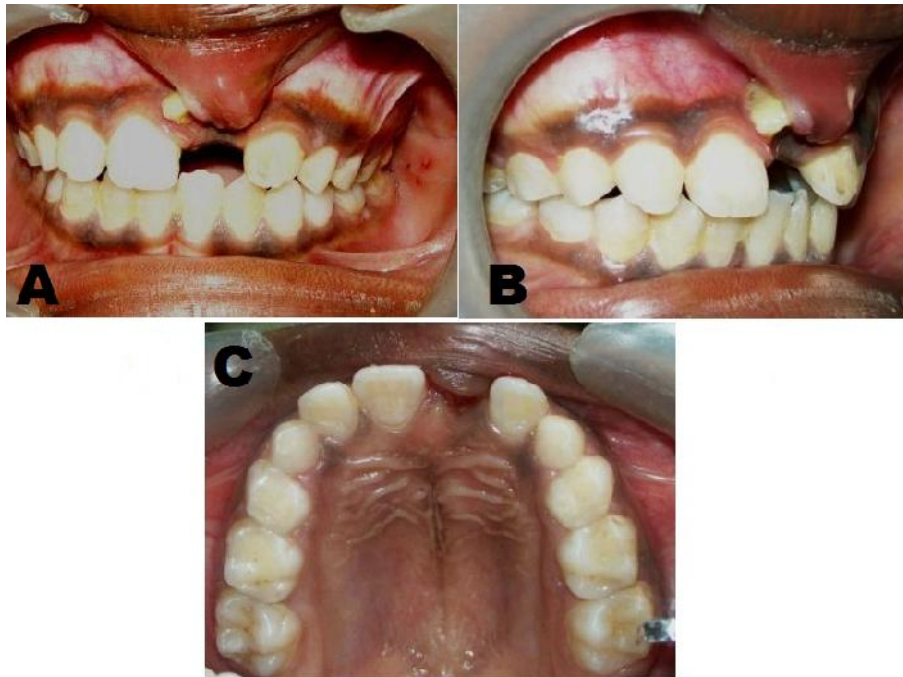


Figure 1: (A) Pre-treatment intra oral frontal photograph, (B) Pre-treatment intra oral right lateral photograph, (C) Pre-treatment upper occlusal photograph.

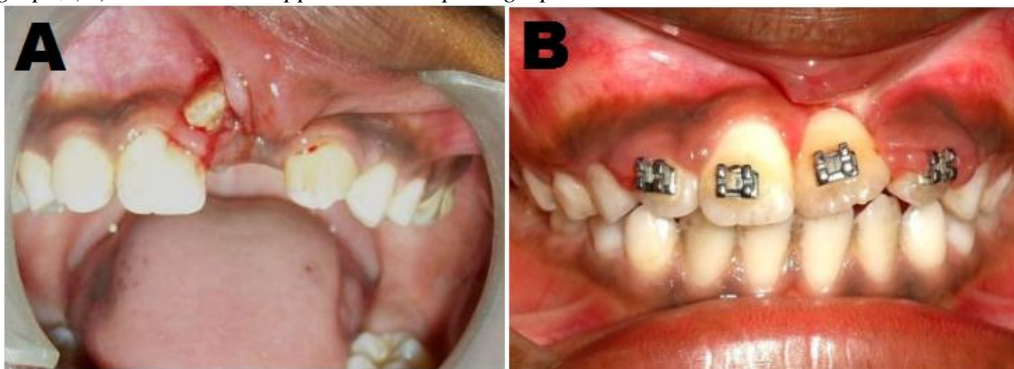


Figure 2: (A) The ectopically erupted incisor was exposed and view of the pseudo pouch with edematous borders and a purulent exudation. (B) Fixed orthodontic therapy was needed for extrusion of the left central incisor, note extent of healing of the inner labial mucosa.

TREATMENT OBJECTIVES: We established the following treatment objectives: (1) Recover space in the maxillary arch for the eruption of the Left central incisor, (2) Provide orthodontic traction for the impacted Left central incisor, (3) Create a stable functional occlusion, and (4) Establish adequate attached gingiva and symmetric gingival margins for both maxillary central incisors.

TREATMENT ALTERNATIVES

1. Extraction of the ectopic central incisor, orthodontic space opening and future restoration with a fixed prosthesis when growth had stopped.
2. Extraction of the ectopic central incisor and closure of the space, bringing the lateral incisor into the place of the central incisor, and subsequent prosthetic restoration.
3. Orthodontic space opening, surgical exposure, and traction of the impacted central incisor into its proper position.

38

TREATMENT PLAN: After discussing the possible treatment alternatives, the parents and the clinicians chose to try to save the tooth and bring it into its proper position. Treatment consisted of fixed orthodontic treatment, surgical exposure, and traction of the impacted left central incisor from a horizontal to a vertical position and its alignment to obtain a normal occlusal relationship.

TREATMENT PROGRESS: Prophylactic antibiotic started for five days and surgically soft tissue band in upper lip mucosa is removed. Purulent fluid is drained and pseudo pouch is removed to prevent further pus accumulation. Antibiotic and chlorhexidine mouth wash started after operative procedure, Sutures removed after 7 days.

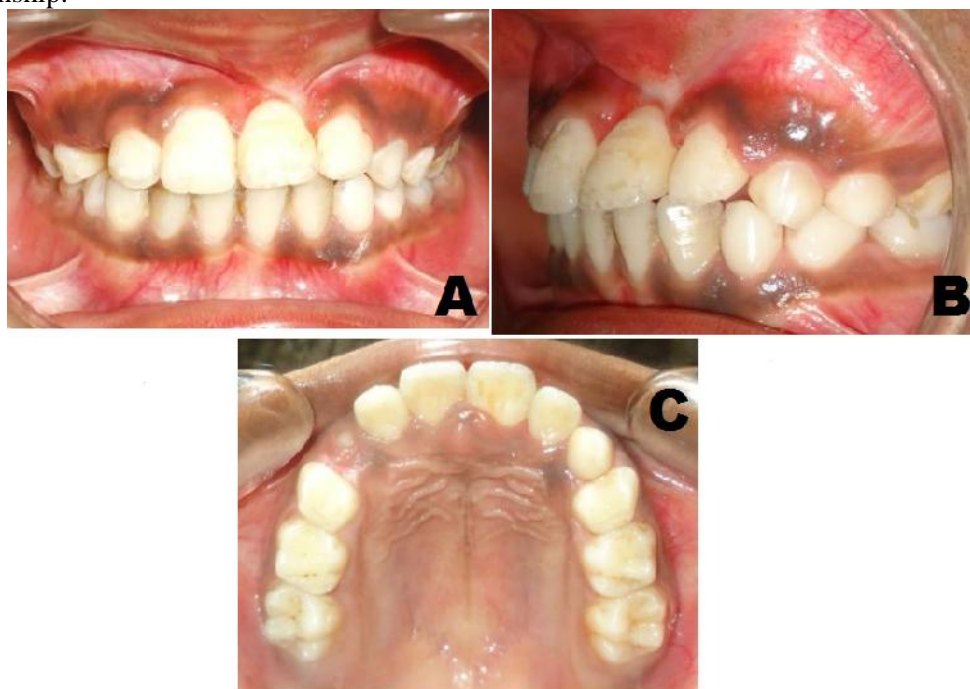

Figure 3: (A) Post-treatment intra-oral frontal photograph, (B) Post-treatment intra-oral left lateral photograph, (C) Post-treatment upper occlusal photograph.

TREATMENT RESULTS

After surgical procedure some surface of tooth will be exposed to bond the attachment. A 0.022×0.025 straight wire brackets were bonded in maxillary incisors. Alignment was done with 0.016 Ni Ti wire followed by 0.017×0.025 and 0.019×0.025 Ni Ti wire. After that 0.019×0.025 stainless steel wire placed. A Ni Ti open coil spring placed between right central and left lateral incisor for opening the space which was lost due to drifting of teeth. A bracket was bonded on exposed surface of left central incisor and traction was started in downward direction. After 6 month of active treatment left central incisor came down in space that was created for it.

In next step it was aligned with adjacent teeth. A 0.0175-inch braided wire was bonded as fixed lingual retainer for retention to prevent relapse. The impacted maxillary

left central incisor was brought into proper alignment with the adjacent teeth and produced a nice smile. In addition to complete healing of the inner labial mucosa, the tooth and supporting tissues appeared to be in good condition. Accessory periodontal treatment with an apically positioned flap was indicated during the traction of the central incisor to provide an adequate width of attached gingiva and ensure alignment of the gingival margin of the positioned tooth with the contra lateral incisor.

DISCUSSION

An ectopic maxillary central incisor in a child during mixed dentition poses a disturbing esthetic dilemma because of its prominent location. Neither dentists nor parents want to wait for complete eruption of the permanent dentition before starting comprehensive orthodontic treatment, especially when the problem can be treated

in the early mixed dentition stage.⁹ However, it is important to properly inform the parents of the possibility of failure before extensive measures are undertaken to save a severely ectopic tooth.¹⁰

Intrusive injuries to primary teeth present the highest risk of damage to permanent tooth germs.¹¹ Intrusive-type injuries to primary incisors most commonly take place in preschool children between 1 and 3 years of age. Several studies have shown that the younger the child at the time of the intrusion injury, the more severe the induced sequelae to the successor tooth.¹²⁻¹³ Despite the occurrence of severe ectopic eruption in the present case, developmental disturbances such as discoloration, hypoplasia, crown or root dilaceration or root angulation were not observed in the affected permanent incisor. Because the trauma had occurred at a relatively later age, the effect on the permanent successor tooth may have been limited to alteration of the eruption pathway. Children with a history of trauma experience a higher percentage of malpositioned incisors compared with those without trauma.¹ This case presents a similar outcome, except that the severity of impact caused the successor to erupt in a highly unusual pattern.

We first determined whether the ectopic tooth could be successfully aligned in its proper position on the basis of following factors used to determine whether successful alignment of an ectopic tooth can take place: (1) the position and direction of the impacted tooth, (2) the degree of root completion, (3) the degree of dilacerations, and (4) the presence of space for the ectopic tooth. Movement of an ectopic central incisor could be complicated because of ankylosis and external root resorption,¹⁴ irregular root formations or an unaesthetic gingival margin after alignment.¹⁵ However, these complications did not occur in this patient.

Considering the position of the ectopically erupted incisor and the insufficient arch length, it seemed difficult to bring the maxillary central incisor into the dental arch. However, regaining sufficient space and ensuring sufficient traction in the right

direction allowed us to move the ectopically erupted tooth into the correct position. Although we initially expected to correct the soft tissue trauma, pus drainage and infection control in upper lip mucosa caused by incisal edge of ectopically erupting left maxillary central incisor, fixed orthodontic therapy was necessary to achieve proper leveling and angulations. Eventually, functional and esthetic problems were solved when the central incisor was positioned in the arch.

When abnormally positioned ectopically erupted incisors are moved into the arch, discrepancies are often observed between the gingival levels of the affected and neighboring teeth. Clinical experience has shown that light forces are more effective than strong force in moving ectopically erupted teeth and achieving a good gingival position.¹⁶ Following fixed orthodontic therapy, the gingiva of the central incisor was brought close to the level of that of the adjacent central incisor, thus eliminating the need for gingival plastic surgery.

CONCLUSION: Trauma to the primary maxillary anterior teeth may affect the eruption of the underlying permanent teeth. Ectopic or unerupted maxillary incisors should be detected early and managed accordingly. The diagnosis can be made with a thorough history and appropriate radiographs. Depending on the position, prognosis of the tooth and patient's esthetic requirement, appropriate treatment plan should be carried out. Surgical exposure and orthodontic traction of an ectopic maxillary incisor is a clinical challenge.

Author affiliations: 1. Dr. Vinay Kumar Verma, MDS, Prof & Head, 2. Dr. Avesh Sachan, MDS, Reader, 3. Dr. Pothuri Ashok, PG Student, 4. Dr. Vishal Singh Badhauria, PG Student, Department of Orthodontics and Dentofacial Orthopedics, Rama Dental College-Hospital And Research Centre, Kanpur, Uttar Pradesh, India.

REFERENCES

1. Brin I, Ben-Bassat Y, Zilberman Y, Fuks A. Effect of trauma to the primary incisors on the alignment of their permanent successors in Israelis.

- Community Dent Oral Epidemiol 1988; 16:104–108.
2. Brin I, Becker A, Shalhav M. Position of the maxillary permanent canine in relation to anomalous or missing lateral incisors: a population study. *Eur J Orthod* 1986; 8:12-16.
 3. Flores MT. Traumatic injuries in the primary dentition. *Dent Traumatol* 2002; 18:287–298.
 4. García-Godoy F, Morbán-Laucer F, Corominas LR, Franjul RA, Noyola M. Traumatic dental injuries in preschool children from Santo Domingo. *Community Dent Oral Epidemiol* 1983; 11:127–130.
 5. Skaare AB, Jacobsen I. Primary tooth injuries in Norwegian children (1–8 years). *Dent Traumatol* 2005; 21:315–319.
 6. Turgut MD, Tekçiçek M, Canoglu H. An unusual developmental disturbance of an unerupted permanent incisor due to trauma to its predecessor — a case report. *Dent Traumatol* 2006; 22:283–286.
 7. Lenzi AR, Medeiros PJ. Severe sequelae of acute dental trauma in the primary dentition — a case report. *Dent Traumatol* 2006; 22:334–336.
 8. Kuvvetli SS, Seymen F, Gencay K. Management of an unerupted dilacerated maxillary central incisor: a case report. *Dent Traumatol* 2007; 23:257–261.
 9. Crawford LB. Impacted maxillary central incisor in mixed dentition treatment. *Am J Orthod Dentofacial Orthop* 1997;112:1-7.
 10. Brand A, Akhavan M, Tong H, Kook YA, Zernik JH. Orthodontic, genetic, and periodontal considerations in the treatment of impacted maxillary central incisors: a study of twins. *Am J Orthod Dentofacial Orthop* 2000;117:68-74.
 11. von Arx T. Developmental disturbances of permanent teeth following trauma to the primary dentition. *Aust Dent J* 1993; 38:1-10.
 12. Andreasen JO, Ravn JJ. The effect of traumatic injuries to primary teeth on their permanent successors. II. A clinical and radiographic follow-up study of 213 teeth. *Scand J Dent Res* 1971; 79:284-294.
 13. Ravn JJ. Developmental disturbances in permanent teeth after intrusion of their primary predecessors. *Scand J Dent Res* 1976; 84:137-141.
 14. Sabri R. Treatment of a Class I crowded malocclusion with an ankylosed maxillary central incisor. *Am J Orthod Dentofacial Orthop* 2002;122:557-565.
 15. Chaushu S, Brin I, Ben-Bassat Y, Zilberman Y, Becker A. Periodontal status following surgical-orthodontic alignment of impacted central incisors with an open-eruption technique. *Eur J Orthod* 2003;25:579-584.
 16. Cozza P, Mucedero M, Ballanti F, De Toffol L. A case of an unerupted maxillary central incisor for indirect trauma localized horizontally on the anterior nasal spine. *J Clin Pediatr Dent* 2005; 29:201–203.

Corresponding Author:

Dr. Ashok Pothuri, PG student,
Dept. of Orthodontics,
Rama Dental College & Hospital, Kanpur,
India.
Contact no: 8960320769
Email: pothuriashok10@gmail.com

How to cite this article: Verma VK, Ashok P, Sachan A, Badhauria V. Early Orthodontic Treatment of Unusual Trauma Caused by Ectopically Erupted Maxillary Central Incisor. *Rama Univ J Dent Sci* 2017 June;4(2):37-41.

Sources of support: Nil

Conflict of Interest: None declared