

Case Report**Mandibular first premolar with two roots: A Case Report.**

Sharma D, Sawhney A, Das D, Srivastava A

Abstract: Mandibular premolars have an aberrant anatomy. Literature is full of reports of extra canals in mandibular premolars, but extra roots in these teeth are quite rare. The possibility of additional root canal should always be considered. A number of variations in the anatomy of premolars have been noticed with major variations seen in number of roots, number of canals and apical foramen. This article reports a case of mandibular first premolar with two roots, which was successful treated with root canal therapy.

Keywords: Abnormal Morphology; Root Canal Morphology; Root Canal Therapy; Mandibular First Premolar

INTRODUCTION

The failure rate of nonsurgical RCT is highest for the mandibular first premolar which came out to be 11.45% according to a study.¹ Some authors have suggested that the mandibular premolar may present with greatest difficulty of all teeth to treat endodontically.² The possible reasons for a high failure rate are the numerous variations in root canal morphology and difficult access to a second canal. There is usually a straight-line access to the buccal canal, while the lingual canal branches at a sharp angle, potentially resulting in a missed canal. A study by Kartal and Yanikoglu, using pooled

data (Table 1) that included first and second premolars, reported a 27.8% incidence of mandibular premolars with more than one canal.¹

Serman and Hasselgren examined full mouth series of radiographs for 547 patients and found that 15.7% of patients had at least one mandibular first premolar with either a divided canal or a root. The second premolars had an incidence of 7% in this study.³ This article reports the clinical case of a mandibular first premolar with two roots with dilaceration.

Table 1: Pooled data for Mandibular First and Second Premolars (courtesy-Ingle J, Bakland L. Endodontics. 6th ed. Hamilton: BC Decker; 2002).

Table 1 Pooled Data for Mandibular First and Second Premolars						
Number of Canals and Apices	Number of Studies Cited	Number of Teeth (Canal Studies)	One Canal	Two or More Canals	One Canal at Apex	Two or More Canals at Apex
	1	187	72.2% (135)	27.8% (52)	76.5% (143)	23.5% (44)

CASE REPORT

A 32 year old male patient reported to the department of Conservative Dentistry and Endodontics at Rama Dental College and Hospital, with the chief complaint of pain in the posterior right mandibular region. Patient's medical history was of no relevance. Clinical examination revealed carious and occlusally attrited mandibular right first premolar. The tooth was tender on percussion.

Radiographic examination of the tooth indicated an unusual anatomy of two roots

with sharp angulation towards distal side, along with widening of apical periodontium and bone loss indicating periapical periodontitis and the necessity for root canal treatment (Figure 1). On the same quadrant there was also unusual anatomy of the second pre molar showing 2 canals as a Vetucci's type V canal anatomy. Similarly a radiograph of the opposite quadrant i.e of the left mandibular premolar was acquired and no significant findings were discovered. It had a single straight canal (Figure 2).

The clinical examination, radiographic examination and thermal tests led to a

diagnosis of symptomatic apical periodontitis of the right mandibular first premolar requiring endodontic therapy. Endodontic access was prepared with a round diamond bur in a high speed airtor handpiece. A sharp DG 16 explorer along with Pro Ultra Ultrasonic tip size no 1 & 2 (Dentsply) was used to locate the canal orifice.

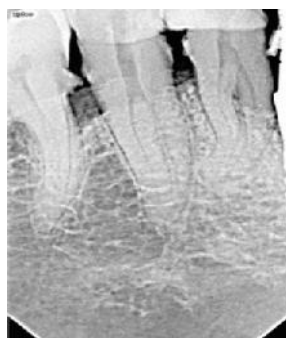


Figure 1: Preoperative radiograph 4th Quadrant showing two rooted First Premolar.

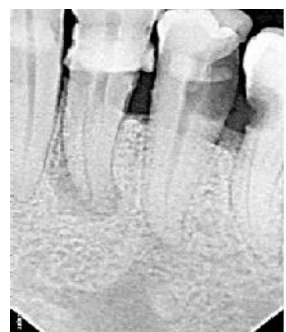

Figure 2: Preoperative radiograph 3rd Quadrant showing normal anatomy.

The canal patency could not be obtained with a 10 # K file (Dentsply, Maillefer) hence a 6 # K flex file (Sybron Endo) was used by precurving in a distolingual direction. Mesial Canal within the mesial root was easily accessed till the apex with a 6 # K flex file whereas there was difficulty in accessing the apical third of the distal canal due to “s” shaped curvature (Figure 3).

To accommodate for the ‘s’ shaped curvature, a sharp bend of 45° was given to the apical portion of 6 # K flex file and re inserted till the apex (Figure 4). The canals were calcified hence EDTA was used regularly and the canals were enlarged with hand files and path files till the patency was established (Figure 5).

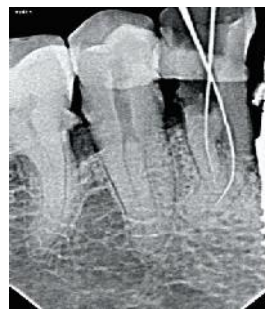


Figure 3: Working Length Determination.

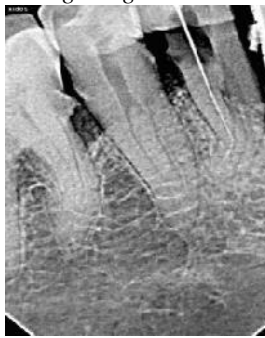

Figure 4: Negotiating Length of curvature.

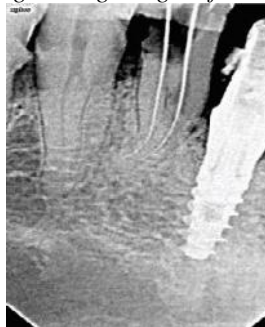

Figure 5: Proper working length determined for both roots after negotiation.

Cleaning and shaping of the canals was performed using Twisted Files (Sybron Endo) under copious irrigation with 5.25% sodium hypochlorite solution followed by 17% EDTA solution. The canals were dried with paper points, and the tooth was temporized. Later, the canals were obturated with cold, lateral compaction of gutta percha cones (Dentsply). A post obturation radiograph was taken to evaluate the quality of obturation (Figure 6).

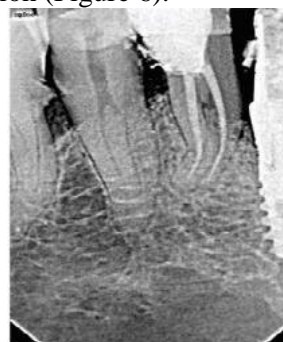

Figure 6: Post operative radiograph.

DISCUSSION

The root morphology of mandibular first premolar can be highly complex and extra root(s) can be found. Scott and Turner described the accessory root of mandibular first premolar as Tome's root.⁴ Trope and colleague's study found significant incidence in ethnic African American group of 400 patients to be 32.8% while the incidence in the Caucasian group of 400 patients was 13.7%. A study of 45 X-chromosome females in Finland found more than one canal in one or more of the mandibular premolars in almost half of the 87 patients studied.¹ Separate canals were found in 23% of the mandibular first premolars and 25% of the mandibular second premolars. The study concluded that X chromosomes have a gene or genes with a regulatory function in root development.

The incidence for 1st mandibular premolar to have 2 separate root is 22% and type IV (2) Vertuci's classification is 10% in Indian population. Whereas for Second mandibular premolar with Type V (1-2) Vertuci's canal configuration is only 4%.⁵ The incidence for Type IV canal in mandibular 1st premolar is 1.5% whereas for Type V canal in mandibular 2nd premolar is 2.5%.¹ Dental pulp is prone to dystrophic mineralization; this mineralization can be so extensive that the entire root canal system is obliterated. As a result, root canal treatment can become a difficult if not impossible task.⁶

Management of calcification can be done with the help of precurving the files, use of EDTA, ultrasonics and Dental Operatory Microscopes. EDTA chemically softens the root canal dentin and is recommended as a lubricant for the use with rotary NiTi files.⁷ One of the challenges in endodontics is to locate canals, particularly in cases in which the orifice has become occluded by secondary dentin or calcified dentin secondary to the placement of restorative materials or pulpotomies. Hence ultrasonic instruments are a safe and effective for calcified canal location and were used in this case.⁸ Similarly when the calcified canal is looked at through the microscope at high magnification, the difference in the color and texture between the calcified canal and the remaining dentin can be easily seen, hence a

combination of magnification with ultrasonics is the best way for negotiating calcified canals.⁹

Root canal preparation has two objectives: thorough debridement of the canal system and shaping of the canal to create a continuously tapered funnel form with the widest diameter at the canal orifice and the smallest diameter at the apical terminus, respecting the original shape of the canal. This "ideal" preparation can be a difficult task to achieve in severely curved root canals or S-shaped canals, especially with traditional stainless steel hand instruments. Nickel-titanium (NiTi) instruments have been marked as a way to overcome these shortcomings. NiTi-alloy has the advantages of super elasticity and the shape memory effect, which can maintain the original canal curvature and create a tapered root canal shape. Hence NiTi rotary instruments were used.¹⁰

CONCLUSION: A variety of factors contribute the challenging endodontic treatment of mandibular first premolars. Successful outcome in such cases is dependent upon careful use of all the available diagnostic aids to locate and treat the entire root canal system. Careful interpretation of angled radiographs, proper access preparation and a detailed exploration of the tooth are essential prerequisites for a successful treatment outcome.

Author affiliations: 1. Dr. Dhananjay Sharma, PG Student, 2. Dr. Asheesh Sawhney, MDS, Professor. 3. Dr. Debanjan Das, PG Student, 4. Dr. Akshat Srivastava; PG Student. Department of Conservative Dentistry and Endodontics. Rama Dental College, Hospital and Research Centre. Kanpur-208024, Uttar Pradesh.

REFERENCES

1. Ingle J, Bakland L. Endodontics. 6th ed. Hamilton: BC Decker; 2002.
2. Slowey R. Root canal anatomy. Road map to successful endodontics. Dent Clin North Am. 1979 23:555-573.
3. Walton R, Torabinejad M. Principles and practice of endodontics. 2nd ed. Philadelphia: W B Saunders Co 1996.
4. Scott R, Turner C., 2nd. The anthropology of modern human teeth. Cambridge: Cambridge University Press 2000.

5. Singh.S & Pawar M. Root Canal Morphology of South Asian Indian Mandibular Premolar Teeth; J Endod. 2014 Sep;40(9):1338-1341
6. Ngeow C, Thong L. Gaining access through a calcified pulp chamber: a clinical challenge. Int Endod J 1998; 31: 367-371
7. Hulsmann M, Heckendorff M. Chelating agents in root canal treatment: mode of action and indication of use. Int Endod J Sept.200;3 36:810- 830.
8. Plotino G, Pameijer CH, Grande NM, Somma F. Ultrasonics in Endodontics: A Review of the Literature; J Endod. 2007 Feb;33(2):81-95.
9. Kim S, Baek S. The microscope and endodontics; Dent Clin N Am 48 (2004) 11–18
10. Ding-ming H, Hong L. Study of the Progressive Changes in Canal Shape After Using Different Instruments by Hand in Simulated ‘S’ Shaped Canals. J Endod. 2007 Aug;33(8):986-989.

Corresponding Author:

Dr. Dhananjay Sharma
Dept. of Conservative Dentistry and
Endodontics
Rama Dental College Hospital and Research
Centre, Kanpur-208024, U.P
Contact no: 8130634822
Email; dr.dhananjaysharma@gmail.com

How to cite this article: Sharma D, Sawhney A, Das D, Srivastava A. Mandibular first premolar with two roots: A Case Report. Rama Univ J Dent Sci 2017 June;4(2):26-29.

Sources of support: Nil

Conflict of Interest: None declared